

# Grant's Dissection Video Collection

**Grant's Dissection Videos** are a collection of 77 high-resolution videos, totaling more than 14 hours, that demonstrate the Grant's method of cadaver dissection sequences, as described in the renowned Grant's Dissector text.

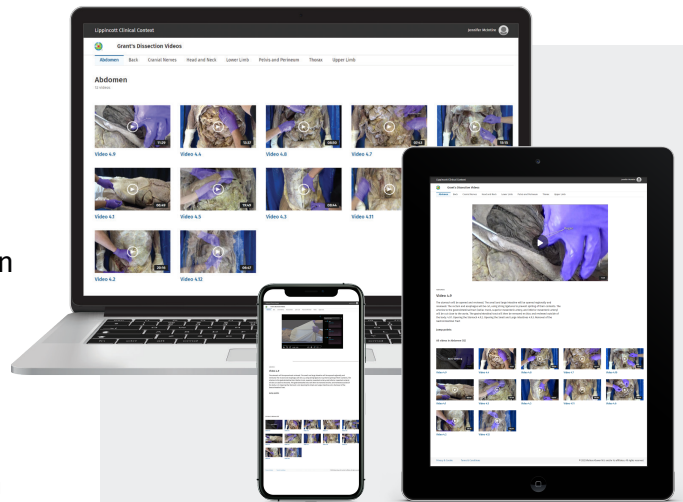
Organized by body region, each video includes narration by Dr. Alan Detton and on-screen labeling showing students:

- What they are expected to achieve in lab
- The steps required for each dissection
- The information they need to learn for practical exam

## Why Grant's Dissection Videos?

- **Ideal for preparation and review** in the gross anatomy lab environment
- **Real cadaver specimens** provide the anatomical detail students need to recognize important relationships revealed through dissection
- **Shows students the proper steps** for dissections and the information they need to learn for practical exams
- **Enables independent learning** and frequent viewing by students
- **Greatly improves student confidence** and makes their use of lab time more efficient
- **Benefits students** that do not have access to a dissection lab, or have limited time or access
- **When combining Grant's resources** – including Grant's Atlas of Anatomy and Grant's Dissector – both faculty and students have a consistent presentation and sequence that will allow for a deeper and more meaningful understanding of anatomy

*Designed to support and enhance anatomy education across healthcare programs*



- **Searchable by video title and description**, making it easy to get to relevant content
- **Variable video play speeds** (.5x, 1x, 1.5x, 2x) allow users to view or review at a comfortable pace
- **Video picture-in-picture** enables users to view a video while browsing additional content
- **Related video gallery** enables viewers to easily move throughout anatomically related videos
- **Key video segments** are listed and linked so viewers can access content quickly
- **Durable URLs** allow faculty to embed links into syllabi
- **Institutional access** via IP validation, OpenAthens, Shibboleth and OneID
- **On-demand usage** reporting available through Adobe Analytics
- **Contains clear narration**, on-screen labeling including captions in Spanish

Contact your local rep or email  
[sales@ovid.com](mailto:sales@ovid.com)

# Grant's Dissection Video Collection

## Contents

### 1. BACK

- 1.1. Skin and Superficial Fascia of the Back (08:18)
- 1.2. Superficial Muscles of the Back (09:20)
- 1.3. Intermediate and Deep Muscles of the Back (09:55)
- 1.4. Suboccipital Region (03:44)
- 1.5. Vertebral Canal, Spinal Cord, and Meninges (11:27)

### 2. UPPER LIMB

- 2.1. Shoulder Region and Posterior Arm (12:46)
- 2.2. Pectoral Region and Superficial Fascia of the Upper Limb (13:03)
- 2.3. Female Pectoral Region and Breast (06:01)
- 2.4. Muscles of the Pectoral Region (08:20)
- 2.5. Axilla (16:10)
- 2.6. Arm (Brachium) and Cubital Fossa (13:35)
- 2.7. Flexor Region of the Forearm (16:19)
- 2.8. Palm of the Hand (19:23)
- 2.9. Extensor Region of the Forearm and Dorsum of the Hand (11:20)
- 2.10. Joints of the Upper Limb (18:55)

### 3. THORAX

- 3.1. Intercostal Space and Intercostal Muscles (06:38)
- 3.2. Anterior Thoracic Wall and Pleural Cavities (11:15)
- 3.3. Lungs (11:47)
- 3.4. Mediastinum (12:32)
- 3.5. External Features of the Heart (12:21)
- 3.6. Internal Features of the Heart (13:50)
- 3.7. Superior Mediastinum (07:50)
- 3.8. Posterior Mediastinum (09:39)

### 4. ABDOMEN

- 4.1. Superficial Fascia of the Anterolateral Abdominal Wall (06:48)
- 4.2. Muscles of the Anterolateral Abdominal Wall (20:15)
- 4.3. Reflection of the Abdominal Wall (08:42)
- 4.4. Peritoneum and Peritoneal Cavity (13:37)
- 4.5. Celiac Trunk, Stomach, Spleen, Liver, and Gallbladder (19:48)
- 4.6. Superior Mesenteric Artery and Small Intestine (08:46)
- 4.7. Inferior Mesenteric Artery and Large Intestine (07:43)
- 4.8. Duodenum, Pancreas, and Hepatic Portal Vein (08:50)
- 4.9. Removal of the Gastrointestinal Tract (11:28)
- 4.10. Posterior Abdominal Viscera (15:14)
- 4.11. Posterior Abdominal Wall (09:58)
- 4.12. Diaphragm (06:47)

### 5. PELVIS AND PERINEUM

- 5.1. Anal Triangle (07:49)
- 5.2. Male External Genitalia and Perineum (07:16)
- 5.3. Male Urogenital Triangle (14:54)

- 5.4. Male Pelvic Cavity (12:15)
- 5.5. Male Urinary Bladder, Rectum, and Anal Canal (07:19)
- 5.6. Male Internal Iliac Artery and Sacral Plexus (11:13)
- 5.7. Male Pelvic Diaphragm (05:53)
- 5.8. Female External Genitalia, Urogenital Triangle, and Perineum (11:16)
- 5.9. Female Pelvic Cavity (16:19)
- 5.10. Female Urinary Bladder, Rectum, and Anal Canal (07:31)
- 5.11. Female Internal Iliac Artery and Sacral Plexus (12:08)
- 5.12. Female Pelvic Diaphragm (05:34)

### 6. LOWER LIMB

- 6.1. Superficial Fascia of the Lower Limb (14:13)
- 6.2. Anterior Compartment of the Thigh (18:56)
- 6.3. Medial Compartment of the Thigh (07:10)
- 6.4. Gluteal Region (10:51)
- 6.5. Posterior Compartment of the Thigh and Popliteal Fossa (09:58)
- 6.6. Posterior Compartment of the Leg (08:10)
- 6.7. Lateral Compartment of the Leg (03:48)
- 6.8. Anterior Compartment of the Leg and Dorsum of the Foot (10:20)
- 6.9. Sole of the Foot (14:26)
- 6.10. Joints of the Lower Limb (21:45)

### 7. HEAD AND NECK

- 7.1. Superficial Neck (07:59)
- 7.2. Anterior Triangle of the Neck (19:53)
- 7.3. Thyroid and Parathyroid Glands (04:27)
- 7.4. Root of the Neck (12:18)
- 7.5. Face (17:10)
- 7.6. Parotid Region (06:37)
- 7.7. Scalp (05:07)
- 7.8. Temporal and Infratemporal Regions (18:39)
- 7.9. Interior of the Skull (10:40)
- 7.10. Brain Removal, Dural Infoldings, and Dural Venous Sinuses (08:55)
- 7.11. Gross Anatomy of the Brain (09:23)
- 7.12. Cranial Fossae (12:21)
- 7.13. Orbit (20:10)
- 7.14. Disarticulation of the Head (07:45)
- 7.15. Pharynx (14:07)
- 7.16. Nose and Nasal Cavity (07:42)
- 7.17. Palate and Pterygopalatine Fossa (12:39)
- 7.18. Oral Region (10:04)
- 7.19. Larynx (08:05)
- 7.20. Ear (05:29)